


Peripheral Nerve Histology

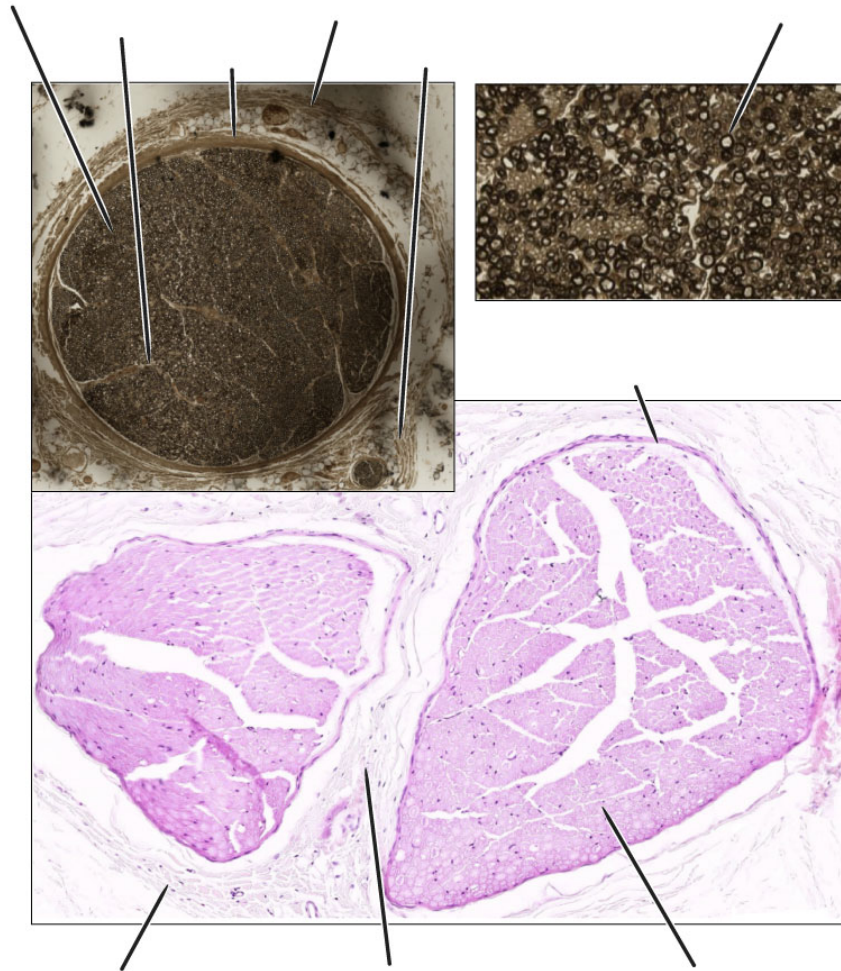


PERIPHERAL NERVE - HISTOLOGY

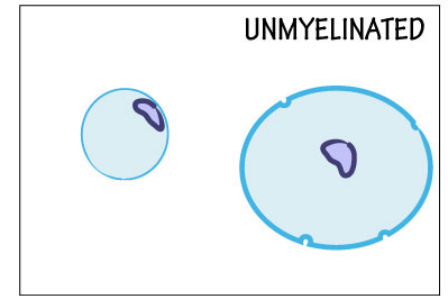
Peripheral Nerve: Cross Section



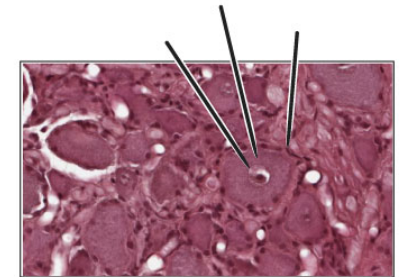
Peripheral Nerve: Cross Section



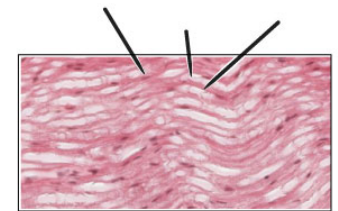

Schwann Cells



Dorsal Root Ganglion



Peripheral Nerve: Longitudinal Section



Notes:
